

Medical Policy:

Cranial Remodeling Band

Effective Date: 02/27/07

Revised: 08/26/08; 08/11/11; 4/16/12

Reviewed/Updates: 05/8/13; 08/27/13

Reviewed/No Updates: 1/28/13; 02/13/14; 02/12/15;
02/11/16; 02/9/17; 02/8/18; 02/14/19; 02/13/20

Policy:

The cranial orthosis, either a helmet or a band, can progressively mold the shape of the cranium. This document addresses the use of the adjustable band or helmet as a post-operative treatment of craniosynostosis or as non-operative treatment for non-synostotic plagiocephaly (asymmetrically shaped head) and brachycephaly (abnormally shaped head; shortened in antero-posterior dimension without asymmetry) in infants.

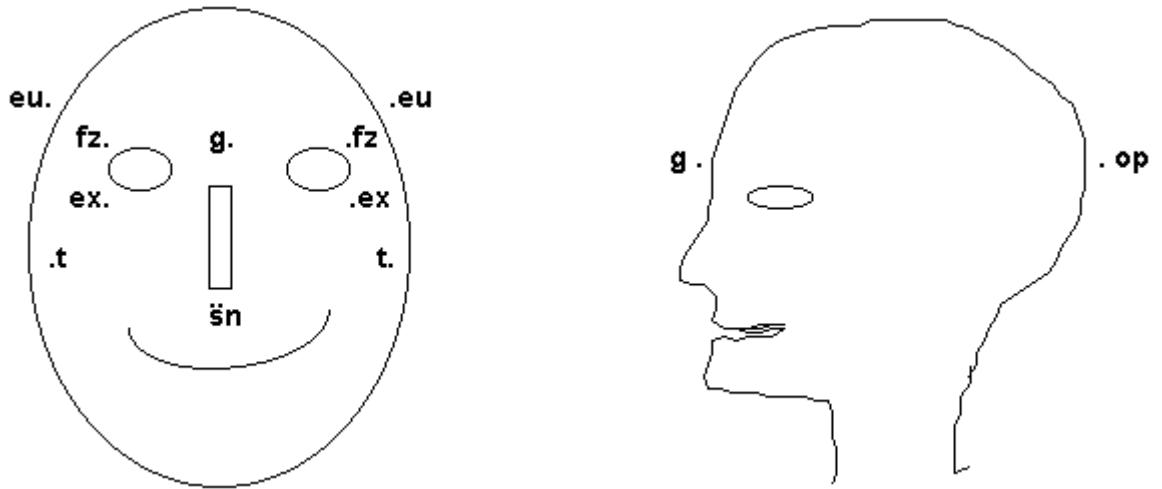
Medically Necessary: In this document, procedures are considered medically necessary if there is a significant physical functional impairment AND the procedure can be reasonably expected to improve the physical functional impairment.

Reconstructive: In this document, procedures are considered reconstructive when intended to address a significant variation from normal related to accidental injury, disease, trauma, treatment of a disease or congenital defect. **NOTE:** Not all benefit contracts include benefits for reconstructive services as defined by this document. Benefit language supersedes this document.

VCHCP considers the use of a cranial remodeling band as durable medical equipment medically necessary for moderate to severe positional head deformities associated with premature birth, restrictive intrauterine positioning, cervical abnormalities, birth trauma, torticollis (shortening of the sternocleidomastoid muscle) and sleeping positions in children when banding is initiated at 4 to 12 months of age and the following conditions are met:

1. A 2-month trial of conservative therapy consisting of repositioning the child's head such that the child lies opposite to the preferred position, has failed to improve the deformity and is judged to be unlikely to do so, *and*
2. *One* of the following must be met:
 - a. Anthropometric data (measurements used to evaluate abnormal head shape by measuring the distance in mm from one pre-designated point on the face or skull to another, comparing the right and left sides) verifies that a moderate to severe plagiocephaly is documented by a physician experienced in such measurement. (Note: These measurements are generally obtained by the orthotist fitting the band or helmet.) The most significant measurements used in this initial evaluation are skull base asymmetry, cranial vault asymmetry, orbitotragial depth, and cephalic index.

DIAGRAM:



A difference of asymmetry greater than 6 mm between anthropometric measurements (see diagram above) in *any* of the anthropometric data in the first column of the following table warrants coverage of a trial of orthotic banding to correct the craniofacial deformity:

Anthropometric Data	Measurement	Measures
Cranial base (sn-t on same side)	from right and left subnasal point (sn) to tragus (t)	measures maxillary depth or right and left morphological face height
Cranial vault (fz R-euL, fz L-euR)	from frontozygomatic point (fz) on one side of face to euryon (eu)	measures cranial vault asymmetry
Orbitotragial depth (ex-t, R, L)	from exocanthion point (ex) to tragus (t)	measures orbito-tragion depth (exocanthion)

- b. For brachycephaly evaluation, a cephalic index 2 standard deviations below mean (head narrow for its length) or 2 standard deviations above mean (head wide for its length) warrants coverage of a trial of orthotic

banding to correct the craniofacial deformity in a child after 4 months of age and before 12 months of age. (Note: These measurements are generally obtained by the orthotist fitting the band or helmet.)

Head width (eu - eu)	from euryon (eu) on one side of head to euryon (eu) on the other side	measures greatest transverse diameter or maximal head width
Head length (g-op)	from glabella point (g) to opisthocranium (op)	measures maximal head depth or length

c.

Cephalic index =	$\frac{\text{Head width (eu - eu) x 100}}{\text{Head length (g - op)}}$

d.

Sex	Age	-2SD	-1SD	Mean	+1SD	+2SD
Male	16 days to 6 months	63.7	68.7	73.7	78.7	83.7
	6 - 12 months	64.8	71.4	78.0	84.6	91.2
Female	16 days to 6 months	63.9	68.6	73.3	78.0	82.7
	6-12 months	69.5	74.0	78.5	83.0	87.5

- e. Premature infants with dolichocephalic head shape who have developed a misshapen head secondary to sustained head position.
- f. Infants who develop significant plagiocephaly secondary to a constant head position required for long-term hyperalimentation who do not respond to simple changing of the catheter location allowing the head to be repositioned.
- g. Members with moderate to severe residual plagiocephaly after surgical correction.
- h. Members with excess frontal bossing secondary to sagittal synostosis.

Use of a cranial remodeling banding for persons not meeting these criteria is considered experimental and investigational.

Background

Plagiocephaly (an asymmetrical head shape) is most often the result of an infant spending extended periods of time on their back, typically during sleep. Plagiocephaly can also occur as a feature of other disorders (e.g., craniofacial disorders, torticollis, cervical anomalies) and is categorized as either positional or synostotic (premature union of cranial sutures). Although 1 in 300 infants exhibit variable degrees of plagiocephaly, true sutural synostosis, which interferes with cranium development and may cause increased intracranial pressure, occurs in only 0.4 to 1 per 1000 live births. This does not apply to members with diagnosis of brachiocephaly.

Positional plagiocephaly is treated conservatively and many cases do not require any treatment as the condition may resolve spontaneously when the infant begins to sit up. When the deformity is moderate or severe and a trial of repositioning the infant has failed, a pediatric neurologist, neurosurgeon or other appropriate specialist in craniofacial deformities may prescribe a cranial remodeling band to remodel the misshapen head.

Examples of brands of cranial remodeling bands and helmets include the DOC BAND®, Gillette Children's Craniocap, and the STARband™ Cranial Headband. Average treatment time with the cranial remodeling band or helmet is four and a half months.

A. **Attachments:** None

B. **History:**

Reviewer/Author: Cynthian Wilhelmy, MD; Date: 01/02/07

Committee Review: UM on 02/05/07 & QA on 02/27/07

Updated by W. Rosario, M.D; Date: 8/26/08

Committee Reviews: UM on 11/20/08; QA on 12/09/08

Reviewed/Updates by Albert Reeves, MD; Date: 08/11/11

Committee Reviews: UM on 08/11/11 & QA on 08/23/11

Reviewed/No Changes: Albert Reeves, MD Date: 4/16/12

Committee Reviews: UM on 5/10/12 & QA on 5/22/12

Reviewed/No Changes: Albert Reeves, MD; Date: 1/28/13

Committee Review: UM on 2/14/13; QA on 2/26/13

Reviewed/Updates by Albert Reeves, MD

Committee Review: UM: February 12, 2015; QAC: February 24, 2015

Reviewed/No Updates: Catherine Sanders, MD

Committee Review: UM on 02/12/2015 & QA on 02/24/2015

Reviewed/No Updates by: Faustine Dela Cruz, RN & Catherine Sanders, MD

Committee Review: UM: February 11, 2016; QAC: February 23, 2016

Reviewed/No Updates by: Catherine Sanders, MD & Robert Sterling, MD

Committee Review: UM: February 9, 2017; QAC: February 28, 2017

Reviewed/No Updates by: Catherine Sanders, MD & Robert Sterling, MD

Committee Review: UM: February 8, 2018; QAC: February 27, 2018

Reviewed/No Updates by: Catherine Sanders, MD & Robert Sterling, MD
 Committee Review: UM: February 14, 2019; QAC: February 26, 2019
 Reviewed/No Updates by: Howard Taekman, MD & Robert Sterling, MD
 Committee Review: UM: February 13, 2020; QAC: February 25, 2020

Revision Date	Content Revised (Yes/No)	Contributors	Review/Revision Notes
2/9/17	No	Catherine Sanders, MD; Robert Sterling, MD	Annual Review
2/8/18	No	Catherine Sanders, MD; Robert Sterling, MD	Annual Review
2/14/19	No	Catherine Sanders, MD; Robert Sterling, MD	Annual Review
2/13/20	No	Howard Taekman, MD; Robert Sterling, MD	Annual Review

C. References:

1. Moss SD. Nonsurgical, nonorthotic treatment of occipital plagiocephaly: What is the natural history of the misshapen neonatal head? *J Neurosurg.* 1997;87(5):667-670.
2. Fredrick DR, Mulliken JB, Robb RM. Ocular manifestations of deformational frontal plagiocephaly, *J Pediatr Ophthalmol Strabismus.* 1993;30(2):92-95.
3. Ripley CE, Pomatto J, Beals SP, et al. Treatment of positional plagiocephaly with dynamic orthoticcranioplasty. *J Craniofacial Surg.* 1994;5(3):150-159.
4. Orthomerica Products, Inc. The Global Orthotic Solution [website]. Newport Beach, CA: Orthomerica; 2002. Available at: <http://www.orthomerica.com/>. Accessed May 16, 2002.
5. Cranial Technologies, Inc. Welcome to Cranial Technologies, Inc., Manufacturer of the DOC Band [website]. Tempe, AZ: Cranial Technologies; 2002. Available at: <http://www.cranialtech.com/>. Accessed May 16, 2002.
6. Orthomerica Products, Inc. The STARband™ Cranial Remolding Orthosis [website]. Newport Beach, CA: Orthomerica; 2003. Available at: <http://www.orthomerica.com/products/cranial/starband.htm>. Accessed May 13, 2004.
7. Gillette Children's Specialty Healthcare. Craniocap™ [website]. St. Paul, MN: Gillette; 2003, 2004. Available at: <http://www.gillettechildrens.org/>. Accessed May 13, 2004.
8. Persing J, James H, Swanson J, et al. Prevention and management of positional skull deformities in infants. The American Academy of Pediatrics. Clinical report. Guidance for the clinician in rendering pediatric care. *Pediatrics.* 2003; 112(1):199-202.
9. Institute for Clinical Systems Improvement (ICSI). Cranial orthoses for deformational plagiocephaly. ICSI Technology Assessment Reports. TA #082.

S:\2020\MEDICAL POLICIES

- Bloomington, MN: ICSI; March 2004. Available at:
<http://www.icsi.org/knowledge/detail.asp?catID=107&itemID=1495>. Accessed May 3, 2004.
10. Pollack IF, Losken HW, Fasick P. Diagnosis and management of posterior plagiocephaly. *Pediatrics*. 1997;99(2):180-185.
 11. Wolfe A, Rubenstein A. Congenital, Syntoses. eMedicine Plastic Surgery Topic 190. Omaha, NE: eMedicine.com; updated May 14, 2003. Available at:
<http://www.emedicine.com/plastic/topic190.htm>. Accessed December 14, 2004.
 12. Seymour-Dempsey K, Baumgartner JE, Teichgraeber JF, et al. Molding helmet therapy in the management of sagittal synostosis. *J Craniofac Surg*. 2002; 13(5): 631-635
 13. de Ribaupierre S, Vernet O, Rilliet B, et al. Posterior positional plagiocephaly treated with cranial remodeling orthosis. *Swiss Med Wkly*. 2007; 137(25-26): 368-372.
 14. Govaert B, Michels A, Colla C, van der Hulst R. Molding therapy for positional plagiocephaly: Subjective outcome and quality of life. *J Craniofac Surg*. 2008; 19(1): 56-58.
 15. NHS Quality Improvement Scotland (NHS QIS). Evidence note 16: The use of cranial orthosis treatment for infant deformational plagiocephaly. Glasgow, Scotland: NHS QIS; 2007.